

Glycar Pericardial Patch with Aldecap

Patch model #	size	thickness
	9 X14cm	0.2-0.4cm
	5X10cm	0.2-0.4cm
	2X5cm	0.2-0.4cm
	4X5cm	0.15X0.25cm

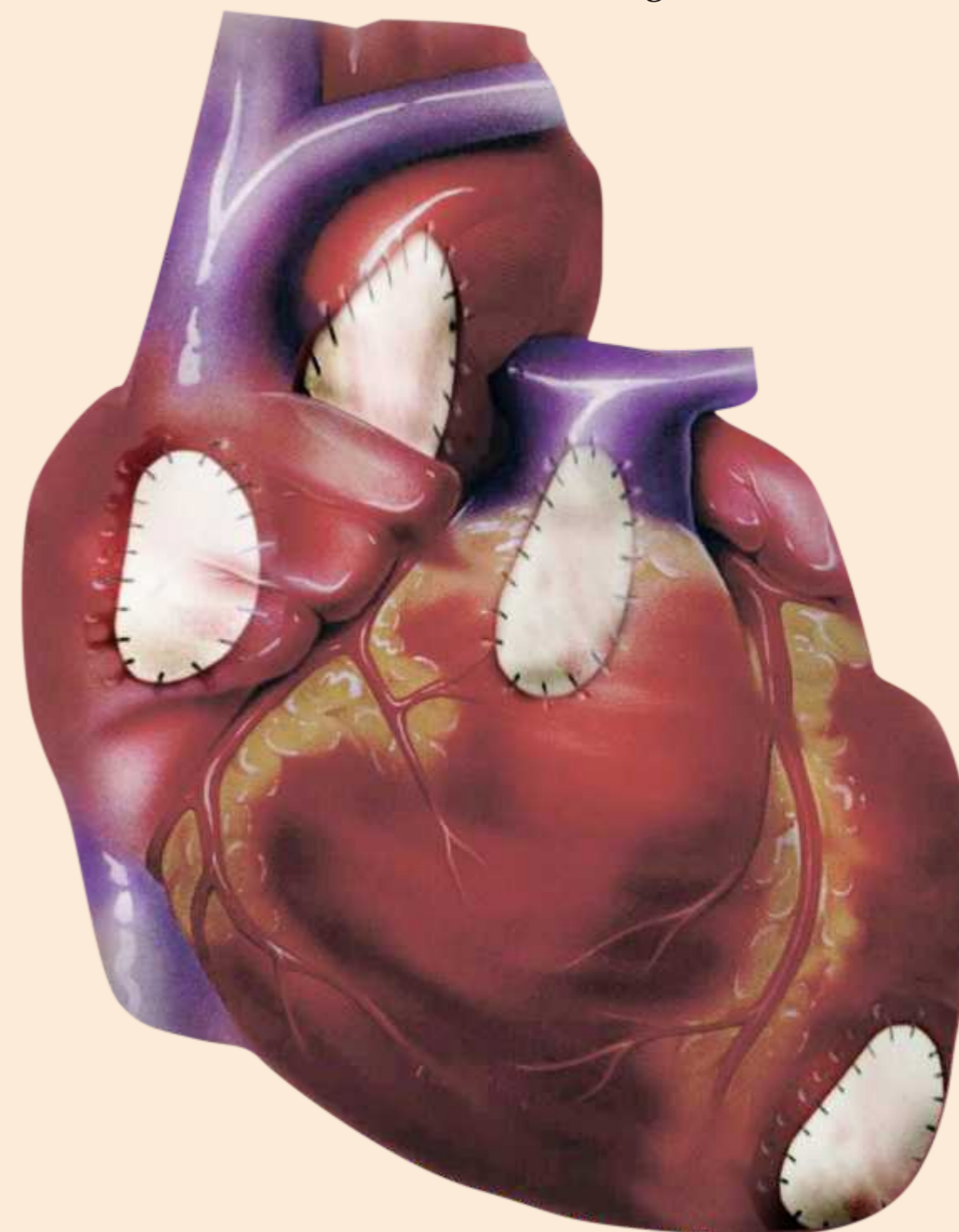
- 1) Exceptional material selection and preparation
- 2) Host healing is invariable. Host inflammatory reaction is minimal
- 3) NO rinsing
- 4) Strength and Pliability

References

1. Crawford FA, Sade RM, Spinale F. Bovine pericardium for correction of congenital heart defects. *Ann. Thorac. Surg.* 1986;41:602-605.
2. Frater RWM, VetterHO, Zussa c, Dahm M. Chordal replacement in Mitral Valve Repair. *Circulation*1990;82(S supp IV);125-130.
3. David TE. .Reconstruction of the mitral annulus- a tenyear experience. *J Thorac.Card Surg*
4. Bjornstad K, Duran RM,et al. Clinical and Echocardiographic followup after aortic valve reconstruction with bovine or autologous pericardium. *Am Heart Jour.*1996;132:1173-8.
5. Frater RWM, Liao K, SeifterE. Stentless. chordally supported, mitral bioprosthesis. In *New Horizons and the Future of of Heart Valve Bioprostheses* 1994;103-119. Edited by S Gabbay, Silent Partners, Austin, Texas.
6. Gong G, Ling E, Seifter E, Factor SM, Frater RWM. Aldehyde tanning; the villain in bioprosthetic calcification. *Eur J Cardiothorac Surg*, 1991;5:288-293.
7. Gong G, Seifter E, Lyman VVD, Factor SM, Blau S, Frater RWM. Bioprosthetic Cardiac Valve degeneration. Role of inflammatory and immune reactions.. *J Heart V Dis.*1993;2:684-693.
8. Frater RWM, Seifter L, Liao K, Wasserman F. Anticalcification, Proendothelial and Anti-inflammatory effect of Post Aldehyde polyol Rx of Bioprosthetic material. In *Advances in Anticalcification and Antidegenerative Treatments of Biological Heart Valves and Coronary Conduits*. Edited by S Gabbay and D Wheatley,1997, 105-113.
9. Hoffman, Gong G, Liao K, Macaluso F, Frater RWM. Spontaneous Host Endothelial Growth on Bioprostheses; Influence of Fixation. *Circulation* 1992;86(Supp II):72-75
10. Moritz et al. Improved spontaneous endothelialization by postfixation treatment of bovine pericardium. *Eur J Cardiothorac Surg*, 1991;5:155-166.
11. Frater RWM, Sussman M, Middlemost S, Walther T, Mohr F, al Halees Z, Shahid M. Quattro Valve Trial at Midterm, Dec 1996 to Nov 2004. *J Heart V Dis.* 2006;15:230-237.
12. Glycar 510k:96:3368.
13. US Patent # 6,174,332. RSA and other worldwide patents.

The manufacturing plant in Irene has annual CE and regular FDA inspections. Glycar SA Pty Ltd is pleased to offer this well tried South African product to South African surgeons. Surgeons and Theatre Nurses are invited to visit the plant.

Glycar SA Pty Ltd, Southern Medical Park,
Albert Rd, Irene 0062
Customer Service: 012 667 1615
Technical Consultation: 001 914 309 5862



Glycar Pericardial Patch with AldeCap Treatment.

For cardiac and vascular reconstruction and repair

Biocompatible, Rinseless, Resists Calcification

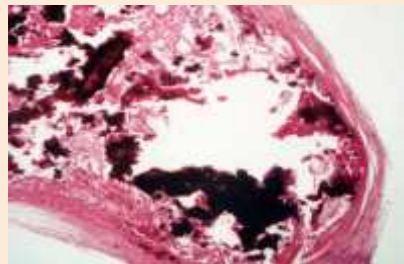
Glycar Pericardial Patch with Aldecap

Glycar Pericardial Patches Exceptional and uniquely thorough preparation

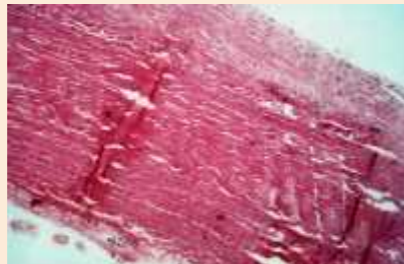
- 1) The Glycar Pericardial Patch is made from selected bovine pericardium. The pericardium is sourced from range fed animals, traceable to birth, certified disease free at slaughter and destined for the European market. Harvesting at the abattoir is done by Glycar staff.
- 2) Processing starts at the abattoir. Each individual piece of pericardium is selected for thickness and an adjacent strip must pass a strength test. Glutaraldehyde crosslinking removes immunogenicity and is followed by the Aldecap process which removes residual aldehyde toxicity. No rinsing is needed before insertion.

3) Aldecap Process produces outstanding biocompatibility

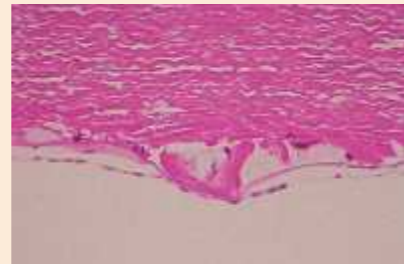
Aldecap proprietary process minimizes host inflammatory reaction at all ages and the tendency to calcification in juveniles. In animals Glycar pericardium has been shown to allow host **endothelial** growth unlike synthetic materials or pericardium treated with aldehydes alone.



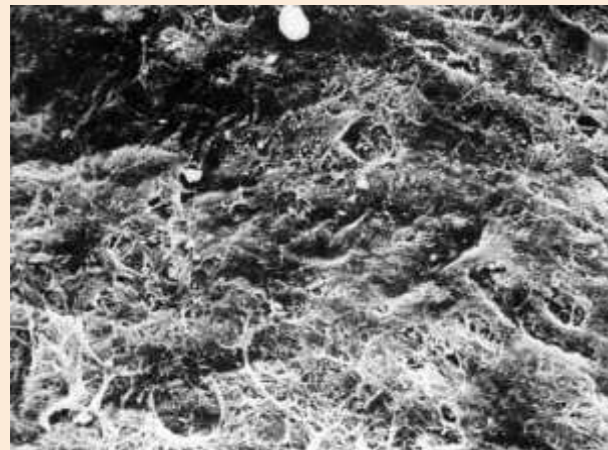
Quattro valve, juvenile sheep, Regular aldehyde Gross calcification, marked inflammation @ 6 months Collagen destroyed




Quattro Valve, juvenile sheep, Aldecap process No calcium, minimal calcification @ 6 months Well preserved collagen



Quattro valve Aldecap, human @ 6 yrs. Collagen intact, no calcium



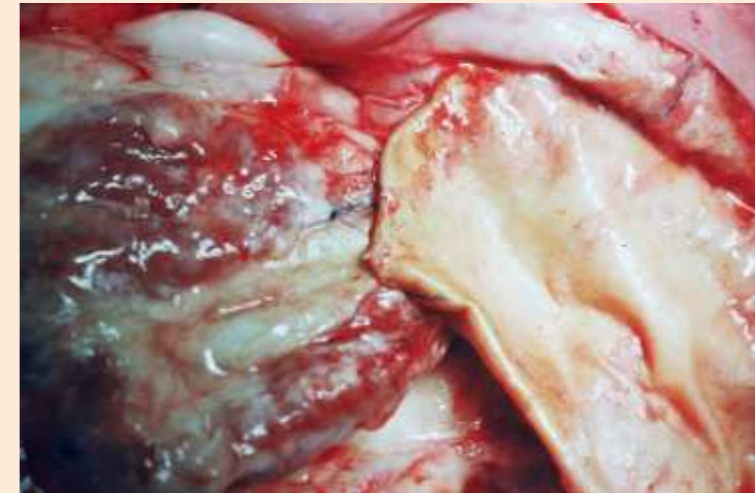
Sheep atrium. 6 months
Glut only Bare collagen,
no endothelium



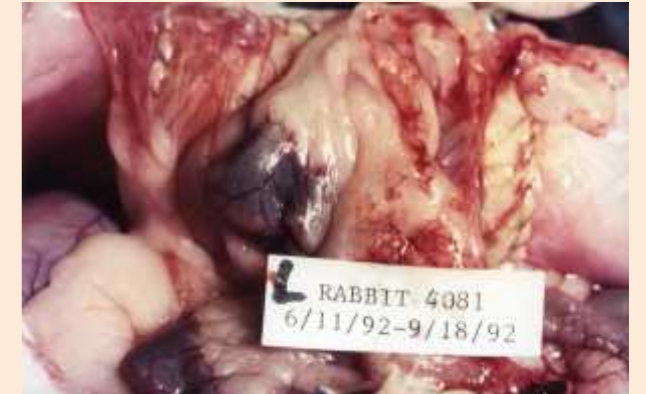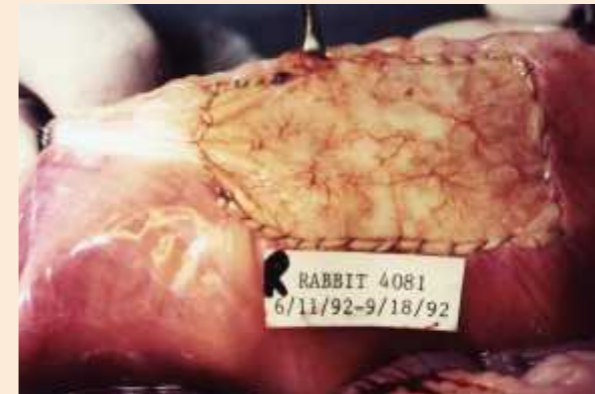Sheep atrium 6 month. Glycar Aldecap,
Endothelial layer

An ideal material for Surgical Repair

- 1) Glycar pericardium is tough, pliable and conforms well to curved shapes. There has been a long history of successful use in high pressure applications. The material is impermeable to fluids and suture holes do not leak. Since 1999 the Glycar pericardial patch material has been used in the USA and Europe with FDA and CE approval. Compared with most synthetic materials and glutaraldehyde tanned pericardium without post-tanning treatment, the host forms only minimal adhesions to Glycar pericardium when used in serous lined cavities such as the pericardium or pleura. On the other hand, at the point of attachment to a host structure, such as a vascular wall or the myocardium, healing is invariably rapid and complete.



Glycar pericardium used as cover for sheep heart after open heart surgery. Animal sacrificed one year postop. No adhesions between endocardium and Glycar pericardium



Rabbit abdominal cavity. Glycar pericardium with Aldecap on rabbit's right. Commercially obtained aldehyde only pericardium on rabbit's left.

Indications for Use

Given the properties of Glycar Pericardium with Aldecap, surgeons have found the material indicated in a wide variety of applications such as:

Adults: aortic root enlargement; aortic, vena caval and peripheral arterial repairs: carotid endarterectomy. Dor procedure; ventricular aneurysm repair; post infarct ventricular wall or septal rupture; mitral and aortic leaflet and chordal repairs;

Post traumatic or post infectious atrio-ventricular, aorto-ventricular separation, or ventricular septal defect; Closure of friable atrium, reinforcement of aortic closure.

Pediatric cases: ASD, AV Defect, VSD, Arterial and Venous enlargements, Ventricular outflow enlargement in combination with other devices and a long list of other applications limited only by the surgeon's imagination,

Non cardiac uses: Post pneumonectomy bronchial stump closure, repair of ruptured bronchus, acquired or congenital diaphragmatic defects. ventral hernia, pelvic floor reconstruction.